

Diabetes Retinopathy prediction Using Machine Learning

Yuvaraj

*UG – Electrical and Electronic Engineering, Sri Krishna College of Engineering and Technology,
Coimbatore, Tamilnadu.*

ABSTRACT

Diabetes mellitus is a persistent condition that affects a variety of body organs of body featuring the retina. Diabetic person Retinopathy (DR) arises from Diabetes Mellitus (DM). In literary works a variety of artificial intelligence formulas have been related to the diagnosis of DR. This includes pair of steps; Including removal and also Category. This study testimonials a variety of approaches utilized for spotting DR based upon the attributes like capillary, microaneurysms, haemorrhages and so on. In the majority of the experiments, retinal fundus graphics were utilized through which photos of the retina were recorded through a fundus video cam. This evaluation bifurcates the diagnosis of DR into pair of approaches; Capillary segmentation and also Recognition of sores. This study matches up the speculative results of a variety of artificial intelligence approaches based upon specifications like level of sensitivity, specificity, AUC, Precision. The results are likewise compared to the deep-seated neural systems and also evaluation of the greatest procedure was offered.

INTRODUCTION

Diabetic person retinopathy (DR) is an illness that has an effect on the capillary current in the retina, which is wrecked as a result of numerous modifications through a collection of metabolic conditions [1]. The capillary current harm their veins as a result of the reduction of pericytes, which are contractile tissues that cover capillary endothelial tissues in the body's venules. Extra sugar particles create this harm in the bloodstream, which clumps with each other in the crafts disrupting blood circulation, a procedure called ischemia. These bloodstream vessels' damage generates microaneurysms, which is a saccular enlargement of the venous point of a retinal capillary due to the absence of blood stream blood circulation. This procedure leads the crafts to shed their impermeability in residential or commercial homes, causing leakages, like haemorrhages or even lipid sweating [2]. Coming from ischemia, pair of primary concerns happen in the retina [3]. The very initial complication is Vascular Endothelial Development Element (VEGF) cytokine healthy protein development, which creates brand-brand new capillaries coming from current ones, called neovessels. The complication of this healthy protein depends on the development of the retina area and also the vitreous humour area. Considering that there's no bloodstream blood circulation, these places will merely expand up till they ruptured, creating haemorrhaging in the vitreous cavity or even drawing the retina apart. That cell growth results merely in the patient's loss of sight. The 2nd complication is plasma leak. As a result of lipid sweating, a fat build-up starts to happen, affecting the macula and also triggering sight reduction. Diabetic person retinopathy may be categorized as coming from the earliest to one of the absolute most progressed phases the moment take a look at the retina's fundus ailment. The condition offers pair of principal types: Non-Proliferative Diabetic person Retinopathy (NPDR) and also Proliferative Diabetic person Retinopathy (PDR) [4]. In addition, NPDR offers 3 subcategories as small, tool, and also intense. The harm of the very initial type is restricted and also doesn't surpass the retina's interior restricting membrane layer. DR is proliferative when the ischemia problems lead to capillary increasing past the retina. PDR consists of very early, high-risk, and also progressed sub-levels. DR is created when a client has actually had diabetes mellitus for a minimum of ten years without a medical prognosis and is also unfamiliar with it. Hereof, the DR may be

stopped if it is spotted very early good enough through wellness check-ups and also step-by-step therapy of diabetes mellitus [5].

Electronic retina fundus graphics were utilized along with computer system sight procedure [6,7] to instantly identify DR in various phases, and also more just lately, by utilizing deep-seated knowing graphic handling technique [8]. Deep-seated knowing (DL) is a tried and tested technique that instantly essences attributes coming from graphics refined through a coating pile of a convolutional neural system [9]. These attributes may establish exactly just what exists in the graphic, and also consequently it works for category functions. DL versions presented a much higher capacity in acknowledging things compared to the individual eye [10]. Nonetheless, this technique still demands significant information and also computational sources to maximize the model's specifications. Within this particular operation, our team popped the question of a DL version to identify retina fundus graphics and also identify the existence of DR in its various phases. The version was enhanced by utilizing transfer-learning coming from DenseNet121 [11] to separate between a healthy and balanced eyeball and also a proliferated one. Our proposition was evaluated over pair of datasets utilizing a cross-testing technique examining the intricacy to get attributes apiece. The version obtained much a lot better recognition and also screening results experienced over the APTOS dataset along with a precision of 81% and also 59% for every period in anticipating diabetic person retinopathy existence in fundus oculi graphics.

LITERATURE REVIEW

Diabetes mellitus is an illness which develops when the pancreas performs certainly does not secrete good enough insulin or even the physical body is not able to procedure it correctly. As diabetes mellitus progresses, the condition gradually affects the blood circulation unit featuring the retina and also develops due to long-term gathered harm to the capillary, decreasing the sight of the individual triggering diabetic person retinopathy. After 15 years of diabetes mellitus, approximately 10% of individuals come to be careless and also roughly 2% build intense aesthetic disability. Inning accordance with a price quote through WHO, greater than 220 thousand folks globally have diabetes Mellitus [1].

It is the 6th most extensive create of loss of sight with individuals operating grow older in India, creating it the world's diabetic person resource. Retinal graphics got with fundal video cam along with back placed electronic video cam [2] supply practical details approximately the repercussion, attributes, and also condition of the impact of diabetes mellitus on the eye.

These graphics aid ophthalmologists to review individuals to strategy various types of administration and also display the development more properly [3]. The retinal microvasculature is special in that it is the mere portion of the individual blood circulation that may be straight visualised non-invasively in vivo, and also may be quickly captured for electronic graphic evaluation [2].

Previously, Otsu, (1979) [4] showed a nonparametric and also not being watched technique of automated limit assortment for image segmentation. This utilises merely the zeroth- and also the first-order collective instants of the grey-level histogram.

Chaudhuri et alia., (1989) [5] dealt with the complication of spotting capillaries which have typically bad nearby comparisons and also emphasises that the current side diagnosis formula produces unsatisfactory results. They popped the question a driver for include removal based upon optical and also spatial residential or commercial homes of the protest to become identified. Patton et alia., (2006) [2] detailed the segmentation of retinal spots whereupon retinal electronic graphic evaluation is located.

Hatanaka et alia., (2007) [6] explained a boosted technique for spotting haemorrhages in fundus graphics. The total diagnosis program featured 6 phases - graphic digitisation, graphic normalization, removal of optic nerve head, diagnosis of haemorrhage applicants, removal of misleading positives (FP) in the

capillary, and also removal of FPs through include evaluation. Nonetheless, the technique for removal of the capillary for the effective diagnosis of haemorrhage applicants wasn't dealt with right below.

Yun et alia., (2008) [7] popped the question of the automated category of various phases of diabetic person retinopathy - moderate non-proliferative retinopathy, modest non-proliferative retinopathy, intense non-proliferative retinopathy and also proliferative retinopathy utilizing neural system coming from 6 attributes removed coming from the retinal graphics.

Diabetes mellitus is an illness which develops when the pancreas doesn't secrete good enough insulin or even the physical body is not able to procedure it correctly. As diabetes mellitus progresses, the condition gradually affects the blood circulation unit featuring the retina and also develops due to long-term gathered harm to the capillary, decreasing the sight of the individual triggering diabetic person retinopathy. After 15 years of diabetes mellitus, approximately 10% of individuals come to be careless and also roughly 2% build intense aesthetic disability. Inning accordance with a price quote through WHO, greater than 220 thousand folks globally have diabetes mellitus [8].

The earliest electronic retina fundus pictures were identified utilizing hand-engineering drawn-out functions with empirical gotten specifications.

Among these functions existed by Cree et alia. [9]. The writers have confirmed that computer system vision methods were appropriate to immediately identify microaneurysms. Their experiments relied upon simple morphological and also thresholding methods utilizing 8 functions amongst pixel location and also complete pixel strength, determined on each prospect. The suggested technique attained outcomes equivalent to those gotten by clinicians, confirming that automated microaneurysm discovery can be utilized for analysis objectives. In more current functions, the techniques were advanced to identify not just microaneurysm in the fundus pictures, yet likewise the phase of diabetic person retinopathy.

As input, 6 devices were utilized for every function worth stating over and also 4 devices as result, one for every extent of DR. Nayak et alia. [10] suggested an approach executing a photo preprocessing with flexible histogram equalization to be more refined by morphological procedures and also appearance evaluation to remove functions regarding capillary. A multilayer perceptron refined the drawn-out functions. The style contained 4 inputs taking into consideration the blood vessel location and also the border of the exudate location, and also appearance. Inputs were refined by 2 concealed layers with 8 devices each in the past the departure with 2 devices to categorize the typical retina stood for by '01', the nonproliferative DR stood for by '10', and also the proliferative DR stood for by '11'.

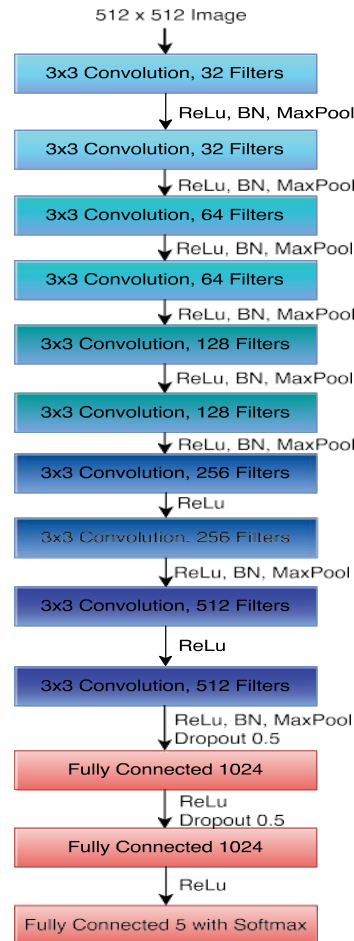Rosas et alia. [11] suggested the acknowledgement of a microaneurysm, utilizing computer system vision methods to preprocess the picture. First of all, the nonuniform lighting was lowered, and also the grayscale intensities were normalized to get 2 functions. The initially functions utilized major element evaluation to differentiate the round-shaped candidates' area, and also the 2nd one utilized radon functions to matter the number establish of distinct angle worths. Those functions were after that passed to an ordered system of classifiers made up of 2 perceptron devices to discover the limit called for to identify if there's a microaneurysm or otherwise in the area.

Hand-crafted drawn-out functions call for specific understanding and also empirical results in attaining exact microaneurysm discovery in electronic pictures. Hereof, current picture refining breakthroughs automated the function purchase phase from raw pictures to beneficial info utilizing convolutional neural networks [12]. Lots of category jobs utilize deep discovering techniques with a big pile of convolutional layers to obtain functions from the network's input. One initially strategy existed by Gargeya et alia. [13], where the writers automate the DR testing. The recognition outcomes got an AUC of 0.95 in the Messidor dataset utilizing a 5-fold cross-validation method. Another work suggested by Dutta et alia. [14], provided a multilayer perceptron outperforming a convolutional neural connect with 83.6%, utilizing drawn-out analytical functions such as typical, average, basic discrepancy, optimal, and also minimal. A

computer-aided DR medical diagnosis system was suggested by Mansour refining the picture with history subtraction to more be refined by the AlexNet version and also get functions. These functions are after that refined by an extremely vector maker (SVM) formula utilizing a 10-fold cross-validation method. The outcomes revealed that using function decreased in the past SVM refining enhances the outcomes getting to a 97.93% of recognition precision.

Kumar et alia. [15] suggested an ensemble strategy of 5 deep discovering designs, which executed well with unbalanced information, accomplishing 70% of recognition precision. One current strategy existed by Gadekallu et alia. [16], that provided a deep discovering version maximized by a smart computer and also using PCA, accomplishing a precision of 96%. Another work by Majumder et alia. [17] suggested a real-time formula to be utilized in mobile phones with a precision of 87.4%, concentrating on a lightweight and also effective version.

The in the past stated methods experienced the problem in distinguishing the acknowledgement between 4 DR phases. This obstacle ends up being noticeable after some functions contrast their propositions as a binary category in between a healthy and balanced and also harmful eye. Furthermore, the absence of examination datasets to verify the specificity of the version ready by certified employees, as suggested in [18].



FUNDUS OCULI SUGGESTED CATEGORY

An approach with the ability to refine retinal fundus pictures for very early discovery of diabetic person retinopathy and also its level, if offered, is suggested. For this function, a deep discovering version with

move discovering is utilized to examine various pictures that are formerly ready, acquiring an inference of how most likely is the presence of diabetic person retinopathy amongst 5 various courses specified as No NPDR, Mild NPDR, Tool NPDR, Serious NDPR, and also Proliferative DR.

CNN STYLE

The suggested version is based upon the DenseNet121 style [11] that gets an RGB photo of 224×224 pixels. The weights were formerly skilled with the ImageNet dataset and also utilized to get enough functions to maximize the weights of the completely linked layer as result. The convolutional layers are likewise called the function removal phase and also the last layer as the category phase. The version result offers a softmax activation to mark chances per course. A unique function of DenseNet is that each result of a convolutional layer is concatenated to the succeeding layers of the same obstruct as received Number 1. When the convolutional layers procedure the picture, the functions gotten are passed to the category phase. 2 completely linked layers become part of the classifier. Its initial layer includes 1024 devices with a ReLU activation, complied with by a failure layer with a likelihood of 50% and also another layer with 1024 devices and also ReLU activation. The last layer offers 5 devices with a softmax activation.

RETINA PICTURES DATASET

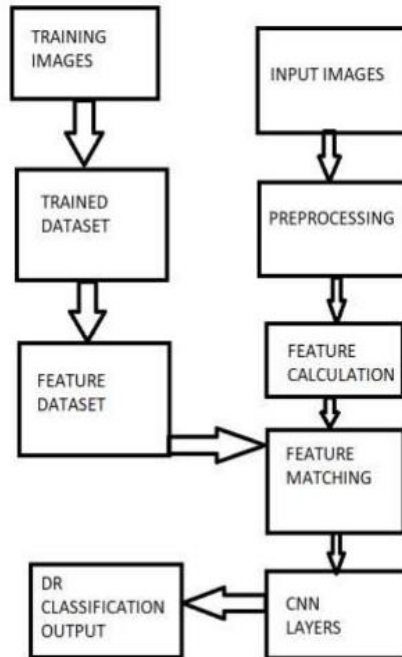
For this work, 2 datasets were utilized as a cross-testing strategy to inspect the model's capability to obtain intricate functions for the various courses stated in Area 2.2 and also the benefits of each dataset. The initial dataset is APTOS, openly offered in the Kaggle system, including 3662 classified pictures for education and also 1928 unlabeled pictures for screening objectives. The 2nd dataset is offered by signing up on the website that handles the Messidor dataset, including 1744 unlabeled pictures for educating. The Messidor dataset [28] makes up 872 DR assessment photos of 2 macula-centred eye fundus pictures from both left as well as appropriate eyes. The ground fact details for the pictures were from a third-party resource. All the pictures offer the same layout of the fundus oculi; in the facility of a vast picture, the eyes exist with a black history. The APTOS dataset was released as a competitor under the same system, with fundus oculi pictures taken under various problems as well as dimensions. For this instance, the dataset writers give the ground fact information just for the educating subset, therefore, we don't utilize the screening subset. Both datasets are high-resolution pictures as well as with an unbalanced variety of pictures for each of the 5 courses. More information regarding course circulation remains in Table 1. As preprocessing, all the pictures in both datasets were cropped and settled from the facility, leaving simply one of the most integral parts of the picture, the retina's fundus. Furthermore, they were resized to 224×224 pixels, specified to shape the pretrained DenseNet model's input, consisting of the preprocessing technique as recommended in their initial operation [11].

OUTCOMES

The education of our proposition was enhanced by utilizing the Adam formula with an understanding price of 1×10^{-5} with the categorical cross-entropy loss work. On top of that, all the design specifications were upgraded throughout 50 epochs utilizing the very early stop technique to avoid overfitting. Both datasets were utilized for education, recognition, as well as screening objectives executed as cross-testing. Therefore, if the APTOS dataset is utilized to maximize the design, 80% is utilized for education as well as 20% for recognition, leaving the Messidor dataset for screening. Equivalently, if Messidor is utilized to maximize the design, the same percentage is utilized for educating as well as recognition, leaving the APTOS dataset for screening.

To contrast, the outcomes in between each dataset utilized for educating, the precision, accuracy, remember, f1-score, the receiver running particular (ROC) contour, as well as the location, under the ROC contour are utilized. Table 2, as well as Table 3, offer the metrics for recognition as well as screening outcomes, specifically. In both Tables, DS implies dataset, as well as in Table 3 just, the APTOSMess as well as MessAPTOS are the screening metrics for the Messidor dataset with the design experienced over APTOS as well as the other way around, specifically. Metrics are acquired throughout recognition. APTOS dataset verified to execute much far better throughout recognition in all provided metrics. Bolder worths show the finest efficiency for a particular course in between both datasets. Metrics were acquired throughout the screening. DS columns show datasets utilized for educating as well as screening, where Mess implies Messidor. Bolder worths show the finest efficiency for a particular course in between both datasets.

The design offers a greater precision experienced with the APTOS dataset compared to Messidor in the recognition subset with 81% as well as 64%, specifically. Thinking about the cross-testing, the design experienced over APTOS got to a 59% precision acknowledging the courses in the Messidor dataset, being much far better compared to the educating over Messidor with 33% of screening precision in the APTOS dataset. Observing the metrics throughout recognition, the design learns a far better accuracy, remember, as well as F1-score from the APTOS compared to Messidor datasets for all the courses. Nevertheless, the Serious NPDR course provided much far better arise from Messidor, as well as the PDR tag category wasn't gained from the Messidor dataset.

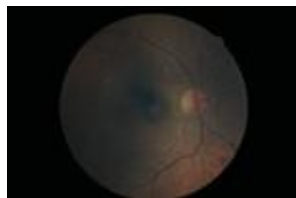

In regards to screening outcomes, the acquired metrics reveal that the design gets to a far better accuracy experienced over Messidor. Nonetheless, a far better remember as well as F1-score is acquired for the design experienced over APTOS. From Number 2 with the ROC contours, it can be valued that the design experienced over APTOS discovered better functions for the majority of the courses compared to the experienced over the Messidor dataset. One of the most challenging courses was the Mild NPDR since the location under the ROC contour was virtually the same for both datasets.

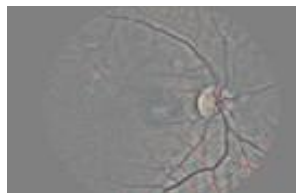
These ROC contours stand for the attribute purchase degree for the design utilizing the cross-testing technique. The MessAPTOS, as well as APTOSMess lines, define the design experienced over Messidor

as well as checked versus APTOS as well as the other way around, specifically. The Mild, as well as Tool NPDR, are one of the most testing differentiable courses in regards to functions. Nonetheless, the APTOS dataset makes up one of the most varied pictures to maximize the specifications for the Tool NPDR course. The Serious NPDR as well as PDR courses were one of the most straightforward to distinguish utilizing both datasets for education in regards to functions. On whole terms, the design experienced over APTOS got much far better functions for all the courses at a reduced false-positive price. The ROC contour for the No DR course. The ROC contour for the Slight NPDR course. The ROC contour for the Tool NPDR course. (design) The ROC contour for the Serious NPDR course. The ROC for the PDR course.

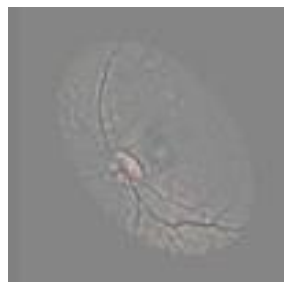A unique provision in this category job is the absence of a standard criteria dataset, developing standard outcomes that need to be utilized as a referral for brand-new propositions. The Messidor dataset was formerly utilized as well as offers a difficult information circulation, and production it appropriates as a criteria dataset. In equivalent, the APTOS dataset offers a much more variate information circulation appropriate to maximize the model's specifications. Thinking about the pictures from Number 3 as well as the worths in the standard pictures from the Messidor dataset reveal far better functions for each of the various 4 DR-related outcomes. Nevertheless, the information circulation from Messidor is not nearly enough to generalize in various picture representations.



a) Original image



(b) Preprocessed image



(c) Augmented image

Dataset picture examples of Messidor (left) as well as APTOS (appropriate). Both datasets were utilized in this operation as a cross-testing technique. Inside out are an example for each course. Initially one is

a healthy and balanced eye. In the centre are nonproliferative diabetic person retinopathy subcategories, as well as last offers a proliferative diabetic person retinopathy.

CONVERSATION

A standard contrast was acquired utilizing the operation provided by Gadekallu et alia. [8], where the design recommended offers a solitary result for a healthy and balanced or DR-affected eye. We combined the 4 DR-related outcomes into one device to execute an ideal contrast with the standard. The recognition outcomes were provided as a base metrics contrast since the writers don't define the examination dataset utilized to acquire the metrics in the formerly discussed operation. Here was presumed that the provided worths represent the recognition subset, which makes up 20% of the initially Messidor dataset variation. Nonetheless, the designs cannot be contrasted straight as a result of information distinctions as well as the absence of details regarding the tag chosen for the outlined metrics. The screening precision accomplished by the design was 61% on both datasets, as well as the criteria metrics exist in Table 4, AM as well as MA are the screening metrics for the Messidor dataset with the design experienced over APTOS as well as the other way around, specifically. The APTOS dataset offers a great accuracy efficiency for the harmful or DR-affected eye as well as great efficiency in remembering as well as F1-score for the healthy and balanced tag. Nevertheless, the design experienced over Messidor much far better acknowledges functions in a specific quality of DR in fundus oculi pictures.

0	3456	0	145	1	34	True Label
1	344	0	27	0	1	
2	543	0	179	5	40	
3	40	0	63	10	15	
4	28	0	23	3	43	
	0	1	2	3	4	Predicted Label

figure 4. Confusion matrix of final classification results

Table 4. Metrics are acquired throughout screening as a binary category. DS columns show the datasets utilized for educating as well as screening. Because purchase, A way APTOS, as well as M implies Messidor. Bolder worths show the finest efficiency for a particular course in between both datasets. Course column Healthy and balanced makes up just No DR course, while Harmful makes up staying ones to attain an ideal contrast in between our proposition as well as previous functions.

CONCLUSION

In this operation, we provided a version to discover diabetic person retinopathy at the beginning as an auxiliary analysis device. The Messidor as well as APTOS dataset aided to inspect the model's attribute purchase for various phases of DR straight from assessment pictures. Our proposition accomplished a

great efficiency under both unbalanced datasets with 81% as well as 64% for APTOS as well as Messidor datasets, specifically. A reasonable contrast of this collaboration with previous techniques is still missing out on offering the absence of a standard examination dataset as well as the method to recommend a brand-new option to identify DR subclasses. A standard dataset ends up being essential offering 2 primary factors. The initially one relates to the datasets resources as well as the establishment which handles as well as makes sure tag honesty. The 2nd one relates to the information utilized to obtain the recognition metrics since each operation offers various recognition information split; therefore, the checked information in between one design as well as another is not the same. Furthermore, several information competitors have no public examination tags, production it challenging to compute the examination metrics. Nonetheless, we showed that the APTOS dataset offers a much more variate circulation of pictures to maximize the design obtaining much far better functions to identify DR subclasses.

In future functions, we recommend producing a criteria dataset to adhere to as a standard contrast. Furthermore, inspect various preprocessing works as well as styles, such as a multilabel method to boost the design efficiency. The multilabel technique originates from the suggestion that a person sort of NPDR shares functions between them. In addition, a discovery formula with a bounding box likewise will be researched.

REFERENCES

- [1] R. Ghosh, K. Ghosh and S. Maitra, "Automatic detection and classification of diabetic retinopathy stages using CNN," *2017 4th International Conference on Signal Processing and Integrated Networks (SPIN)*, 2017, pp. 550-554, doi: 10.1109/SPIN.2017.8050011.
- [2] Doshi, Darshit & Shenoy, Aniket & Sidhpura, Deep & Gharpure, Prachi. (2016). Diabetic retinopathy detection using deep convolutional neural networks. 261-266. 10.1109/CAST.2016.7914977.
- [3] Rashid, Halbast & Mohsin Abdulazeez, Adnan & Abas Hasan, Dathar. (2021). Detection of Diabetic Retinopathy Based on Convolutional Neural Networks: A Review. *Asian Journal of Research in Computer Science*. 1-15. 10.9734/AJRCOS/2021/v8i330200.
- [4] Shorav Suriyal, Christopher Druzgalski, Kumar Gautam, "Mobile Assisted Diabetic Retinopathy Detection using Deep Neural Network," MARCH 19–24, 2018 ISBN: 978- 1-5386-5475-0 IEEE CATALOG NUMBER: CFP1818GART 978-1-5386-5475-0/18/\$31.00 ©2018 IEEE
- [5] Amol Prataprao Bhatkar, Dr. G.U.Kharat, "Detection of Diabetic Retinopathy in Retinal Images using MLP classifier" 978-1-4673-9692-9/15 \$31.00 © 2015 IEEE DOI 10.1109/iNIS.2015.30
- [6] Mohamed Chetoui, Moulay A. Akhloufi, Mustapha Kardouchi, "Diabetic Retinopathy Detection Using Machine Learning and Texture Features," 978-1-5386- 2410-4/18/\$31.00 ©2018 IEEE
- [7] XIANGLONG ZENG, HAIQUAN CHEN, YUAN LUO AND WENBIN YE, "Automated Diabetic Retinopathy Detection Based on Binocular Siamese-like Convolutional Neural Network" 2169-3536 (c) 2018 IEEE
- [8] Z. A. Omar, M. Hanafi, S. Mashohor, N. F. M. Mahfudz, M.Muna'im, "Automatic diabetic retinopathy" 978-1- 5386-0383-3/17/\$31.00 ©2017 IEEE [6] Yashal Shakti Kanungo, Bhargav Srinivasan, Dr. Savita Choudhary, "Detecting Diabetic Retinopathy using Deep Learning" 978-1-5090-3704-9/17/\$31.00 © 2017 IEEE
- [9] Deepthi K Prasad, Vibha L, Venugopal K R, "Early Detection of Diabetic Retinopathy from Digital Retinal Fundus Images" 978-1-4673-6670-0/15/\$31.00 ©2015 IEEE
- [10] Enrique V. Carrera, Andr es Gonz alez, Ricardo Carrera, "Automated detection of diabetic retinopathy using SVM" 978-1-5090-6363-5/17/\$31.00 _c 2017 IEEE



- [11] Karkhanis Apurva Anant¹ Tushar Ghorpade¹ Vimla Jethani, “Diabetic Retinopathy Detection through Image Mining for Type 2 Diabetes” 978-1-4673-8855- 9/17/\$31.00 ©2017 IEEE
- [12] Ratul Ghosh, Kuntal Ghosh, Sanjit Maitra, “Automatic Detection and Classification of Diabetic Retinopathy stages using CNN” 978-1-5090-2797-2/17/\$31.00 ©2017 IEEE
- [13] Chen Y-W, Wu T-Y, Wong W-H, Lee C-Y. Diabetic retinopathy detection based on deep convolutional neural networks. 2018 IEEE International Conference on Acoustics, Speech and Signal Processing (ICASSP). 2018;1030–1034.
- [14] Mateen M, Wen J, Nasrullah N, Sun S. Hayat S. Exudate detection for diabetic retinopathy using pretrained convolutional neural networks. Complexity; 2020.
- [15] Shaw JE, Sicree RA, Zimmet PZ. Global estimates of the prevalence of diabetes for 2010 and 2030. Diabetes Research and Clinical Practice; 2010;87(1):4–14.
- [16] Zeebaree DQ, Abdulazeez AM, Zebari DA, Haron H, Nuzly H. "Multi-level fusion in ultrasound for cancer detection based on uniform lbp features," Computers, Materials and Continua. 2021;66(3):3363–3382.
- [17] Price LD, Au S, Chong NV. Optomap ultrawide field imaging identifies additional retinal abnormalities in patients with diabetic retinopathy. Clinical Ophthalmology (Auckland, NZ); 2015;9:527